



Therapeutic efficacy of autologous platelet-rich plasma and polydeoxyribonucleotide on female pattern hair loss

Si-Hyung Lee, MD^{1*}; Zhenlong Zheng, MD, PhD^{2,3*}; Jin-Soo Kang, MD⁴; Do-Young Kim, MD²; Sang Ho Oh, MD, PhD²; Sung Bin Cho, MD, PhD^{2,4}

1. Laboratory of Disease Functional Genomics, Graduate School of Medical Science and Engineering, Korea Advanced Institute of Science and Technology, Daejeon, Korea,
2. Department of Dermatology and Cutaneous Biology Research Institute, Yonsei University College of Medicine, Seoul, Korea,
3. Department of Dermatology, Yanbian University College of Medicine, Yanji, China, and
4. Kangskin Dermatology Clinic, Seoul, Korea

Reprint requests:

Dr. Sung Bin Cho, Department of Dermatology and Cutaneous Biology Research Institute, Yonsei University College of Medicine, 50 Yonsei-ro, Seodaemun-gu, Seoul 120-752, Korea.
Tel: +82 2 2228 2080;
Fax: +82 2 393 9157;
Email: sbcho@yuhs.ac

*The first two authors contributed equally to this work.

Manuscript received: November 15, 2014
Accepted in final form: December 8, 2014

DOI:10.1111/wrr.12250

ABSTRACT

Autologous platelet-rich plasma (PRP) exerts positive therapeutic effects on hair thickness and density in patients with pattern hair loss. The aim of our study was to evaluate the efficacy of intra-perifollicular autologous PRP and polydeoxyribonucleotide (PDRN) injections in treating female pattern hair loss (FPHL). Twenty FPHL patients were treated with a single session of PRP injection, followed by 12 sessions of PDRN intra-perifollicular injection, along the scalp at weekly intervals. Additionally, another 20 FPHL patients were treated with 12 sessions of PDRN injection only. Meanwhile, one half of the backs of two rabbits was injected with the PRP preparation, while the other half was injected with phosphate buffered saline as a control. Tissue samples from the rabbits were analyzed by real-time polymerase chain reaction and Western blotting. Compared with baseline values, patients treated with PRP and PDRN injections exhibited clinical improvement in mean hair counts ($23.2 \pm 15.5\%$; $p < 0.001$) and mean hair thickness ($16.8 \pm 10.8\%$; $p < 0.001$). In addition, patients treated with the 12 sessions of intra-perifollicular PDRN injection alone also showed clinical improvement in mean hair counts ($17.9 \pm 13.2\%$; $p < 0.001$) and mean hair thickness ($13.5 \pm 10.7\%$; $p < 0.001$). Comparison analyses between the two groups revealed that combined therapy with PRP and PDRN induces greater improvement in hair thickness than treatment with PDRN therapy alone ($p = 0.031$), but not in hair counts ($p > 0.05$). The pilot animal study revealed significant up-regulation of WNT, platelet-derived growth factor, and fibroblast growth factor expression in rabbit skin treated with the PRP preparation, compared with control skin. In conclusion, intra-perifollicular injections of autologous PRP and/or PDRN generate improvements in hair thickness and density in FPHL patients.

Female pattern hair loss (FPHL) is the most common type of alopecia in women.¹ Typically, patients with FPHL present clinically with prominent thinning of scalp hair, decreased hair counts, and a retained frontal hairline.² The goal of FPHL treatment ranges from preventing progression of hair loss to restoring hair regrowth by mainly using androgen-dependent and androgen-independent therapeutic modalities, including oral finasteride and topical minoxidil solution.^{1,2} Additionally, adjuvant treatment options of hair transplantation, mesotherapy, nonablative fractional laser treatment, low-level laser therapy, and intra-perifollicular platelet-rich plasma (PRP) injection have been shown to be therapeutically effective in inducing hair follicular regeneration in alopecia patients.¹⁻⁸

PRP promotes wound healing and induces tissue regeneration. Thus, the therapeutic efficacy of PRP has been investigated in many facets of dermatology, including wound healing in the lower extremities, acne scar treatment, fat trans-

plantation, and pattern hair loss.^{3-7,9,10} PRP preparations containing optimal platelet counts of more than 1,000,000 platelets/ μL have been shown to release platelet α -granules sufficient for obtaining satisfactory results.^{6,11,12} α -Granules release chemokines, cytokines, and growth factors that stimulate cell proliferation and differentiation.^{5,6} In our previous preliminary report, we discovered noticeable clinical improvements in patients with male pattern hair loss and FPHL upon the injection of autologous CD34+ cell-containing PRP preparations.⁸

Thus, in this evaluator-blinded study, we set out to assess the efficacy and safety of intra-perifollicular injections of autologous CD34+ cell-containing, leukocyte-rich PRP and/or polydeoxyribonucleotide (PDRN) for treating FPHL. Additionally, a pilot, split-back animal study was performed to investigate the effects of PRP injection on the expressions of WNT, platelet-derived growth factor (PDGF), and fibroblast growth factor (FGF) 9.

MATERIALS AND METHODS

Patients and treatment protocol

A total of 40 Korean female patients (mean age: 33.9 years; age range: 20–60 years) with FPHL were enrolled in this study. Patients were clinically diagnosed with FPHL upon presentation of an increase in miniaturized terminal hair and/or a reduced number of hair on physical examination and phototrichograms, along with negative hair pull tests. Patients who had received topical and/or oral medications, mesotherapy and/or intra-perifollicular injection therapy, fractional laser treatment, low-level laser therapy, intra-perifollicular PRP injection, and hair transplantation for the treatment of FPHL within the preceding 6 months were excluded. This study was approved by the Institutional Review Board of Severance Hospital, Yonsei University College of Medicine in Seoul, Korea.

CD34+ cell-containing, leukocyte-rich PRP was prepared using SmartPreP2 APC+ (Harvest Technologies Corp., Plymouth, MA) and injected in 20 randomly selected participants (mean age: 35.4 years; age range: 20–60 years) upon receiving informed consent. As described in a previous report,⁸ 60 mL of blood obtained from the participants was transferred to tubes containing 8 mL of 4% sodium citrate solution (Baxter Healthcare Corp., Deerfield, IL). The blood was then centrifuged with the SmartPreP2 platelet concentrate system (Harvest Technologies Corp.). Next, each participant's scalp was cleansed with 70% alcohol, and local anesthesia of 2% lidocaine with 1:100,000 epinephrine (3–5 mL) was injected along the frontal, mid, and vertex areas. Then, 0.05–0.1 mL/cm² of the CD34+ cell-containing PRP preparation (4 mL in total) was injected along the scalp. The number of platelets and white blood cells (WBCs) in the PRP prepared from each participant was microscopically counted. At 1 week after the PRP intra-perifollicular injection, 12 sessions of PDRN intra-perifollicular injection were performed at weekly intervals. To do so, the scalp was cleansed with 70% ethanol, and 2 mL of PDRN (Placentex Integro; Mastelli Ltd., Sanremo, Italy) was injected along the frontal, mid, and vertex areas without local anesthesia. During the treatment, a cooling device with cold air (–10 °C; Zimmer MedizinSystems, Irvine, CA) was briefly used to relieve pain.

The other 20 randomly selected patients (mean age: 32.5 years; age range: 23–43 years) were treated with 12 sessions of intra-perifollicular PDRN injection alone at weekly intervals as described above. Participants in both groups were advised to avoid the use of topical medications (including minoxidil, alfatradiol, prostaglandin analogs, and retinoids), oral medications (including anti-androgens and supplementary nutrients), laser or light therapy, and hair transplantation.

Objective and subjective evaluations

As described in a previous report,⁸ hair measurements were performed using a computerized hand-held USB camera PT system (Folioscope, LeedM Corporation, Seoul, Korea) at baseline and at 1 week after the last treatment session. Digital images of the hair were obtained at 40-fold magnification at the “V” point, which was drawn at the intersection of the mid-sagittal line and the coronal line, connecting both tips of the tragus, via phototrichogram scalp measurement using a headband and tapeline.⁸ Thereafter, both the number and the

thickness of hair were measured with Folioscope PT software (LeedM Corporation). Also, at 1 week after the last treatment session, patients were asked to report the incidence and duration of any side effects from the treatment, including scalp edema, blistering, bleeding, oozing, scaling or crusting, erythema, or increased hair loss.

Animal study

Two male New Zealand rabbits (3.0 kg in weight) were used in this animal study, and all experiments were approved by the Committee for the Care and Use of Laboratory Animals at Yonsei University College of Medicine in Seoul, Korea. The experimental rabbits were anesthetized with an intramuscular dose of 1 mg/kg of acepromazine. PRP was prepared by obtaining 20 mL of blood from the central artery of the left ear in each rabbit and transferring it to SmartPreP2 APC+ containing 2.5 mL of 4% sodium citrate solution (Baxter Healthcare Corp.). The blood was then centrifuged with the SmartPreP2 platelet concentrate system. Next, the hair on the back of each animal was removed using clippers, and the back was disinfected with 10% povidone-iodine solution and 70% ethanol. On one half of the backs of each rabbit, 0.05 mL/cm² of the PRP preparation (4 mL in total) was injected, while the other half was injected with the same amounts of phosphate buffered saline (PBS) as a control. At 1, 3, 5, and 7 weeks after the injection of the PRP preparation, skin samples were obtained under anesthesia with an intramuscular injection of 15 mg/kg of Zoletil (Virbac, Milan, Italy) and 5 mg/kg of Rompun (Bayer, Leverkusen, Germany) along the femoral region. The biopsied skin was sutured with Nylon 4-0, and to prevent infections, 5 mg/kg of enrofloxacin was injected into subcutaneous tissue once a day, beginning on the day of the first biopsy until 3 days after the final operation. Additionally, two injections of 0.5 mg/kg of ketorolac were administered on the day of each operation to reduce pain.

Real-time polymerase chain reaction and Western blotting

In the rabbit skin samples, mRNA levels relative to rabbit glyceraldehyde 3-phosphate dehydrogenase were measured by real-time polymerase chain reaction (PCR) using TaqMan Reverse Transcription reagents (Invitrogen, Carlsbad, CA). Table 1 summarizes the primers used in this study. Full-thickness skin samples from the rabbits were homogenized in lysis buffer, and a total of 50 µg of protein per sample was analyzed by denaturing sodium dodecyl sulfate-polyacrylamide gel electrophoresis (SDS-PAGE). Prepared samples were immunoblotted with the following antibodies: anti-WNT5a antibody (ab174963; Abcam, Cambridge, UK); anti-WNT10a antibody (NBPI-69116; Novus, Littleton, CO); anti-PDGF-A (bs-0196R; Bioss, Woburn, MA); anti-PDGF-B antibody (bs-0185R, Bioss); anti-FGF9 antibody (ab9743; Abcam); and anti-β-actin antibody (Sigma-Aldrich, Poole, United Kingdom). Signals were revealed using enhanced chemiluminescence.

Statistical analysis

A normality test was performed for clinical and laboratory data using Kolmogorov–Smirnov test, and then, results were

Table 1. Primer sequences for real-time polymerase chain reaction

Gene	Forward primer	Reverse primer
<i>WNT5a</i>	CGGGACTTTCTCAAGGACAG	CCTTCGATGTCGGAAGTCTGAT
<i>WNT10a</i>	ACGAGTGCCAACACCAGTTC	TCTCTCGGAAACCTCTGCTG
<i>PDGF-A</i>	GGAAGACAGAGCAAGCCAAG	AGGTTGCATCGTCTTTTGTCT
<i>PDGF-B</i>	TGCAGGTGAGAAAGATCGAG	CTGCCACCGTCTCACACTT
<i>FGF9</i>	GGGGAGCTGTATGGATCAGA	TCCAGTGTCCACGTGTTTGT
<i>ACTB</i>	CCAGCACCATGAAGATCAAG	ACATCTGCTGGAAGGTGGAG

analyzed by the linear mixed models (MIXED) procedure with Bonferroni post hoc analysis, independent two-sample *t* test, paired *t* test, and Pearson correlation analysis by parametric criteria using SAS software version 9.2 (SAS Institute Inc., Cary, NC). Differences with *p*-values of less than 0.05 were considered statistically significant.

RESULTS

Effect of autologous PRP and/or PDRN injection on hair regeneration

At baseline, there were no statistical differences in the participants' age (*p* > 0.05), number of hair (*p* > 0.05), or hair thickness (*p* > 0.05) between the PRP and PDRN treatment group and the PDRN alone treatment group. One week after the final treatment session with PRP and PDRN injections, patients exhibited clinical improvements in both mean hair counts (23.2 ± 15.5%; *p* < 0.001) and mean hair thickness (16.8 ± 10.8%; *p* < 0.001), compared with baseline values (Figures 1 and 2A). In addition, patients treated with 12

sessions of intra-perifollicular PDRN injection alone also showed clinical improvements in mean hair counts (17.9 ± 13.2%; *p* < 0.001) and mean hair thickness (13.5 ± 10.7%; *p* < 0.001), compared with baseline values (Figures 2B and 3). Comparison analyses between the two

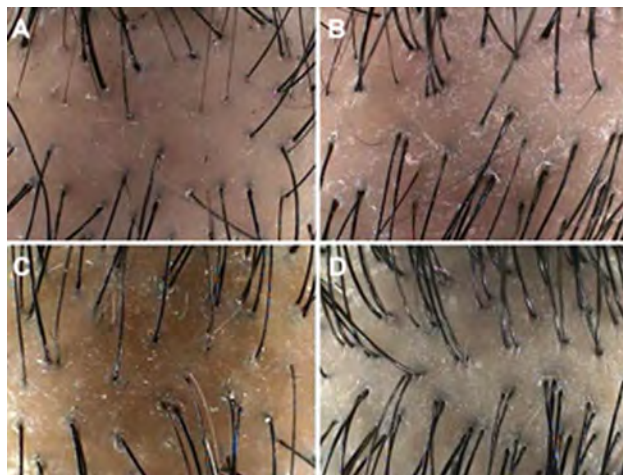


Figure 1. Digital images of the hair at the "V" point in (A, B) patient 1 and (C, D) patient 15 with female pattern hair loss (A, C) before and (B, D) 1 week after the last session of combined treatment with injections of intra-perifollicular CD34+ cell-containing, leukocyte-rich platelet-rich plasma (PRP) and polydeoxyribonucleotide (PDRN).

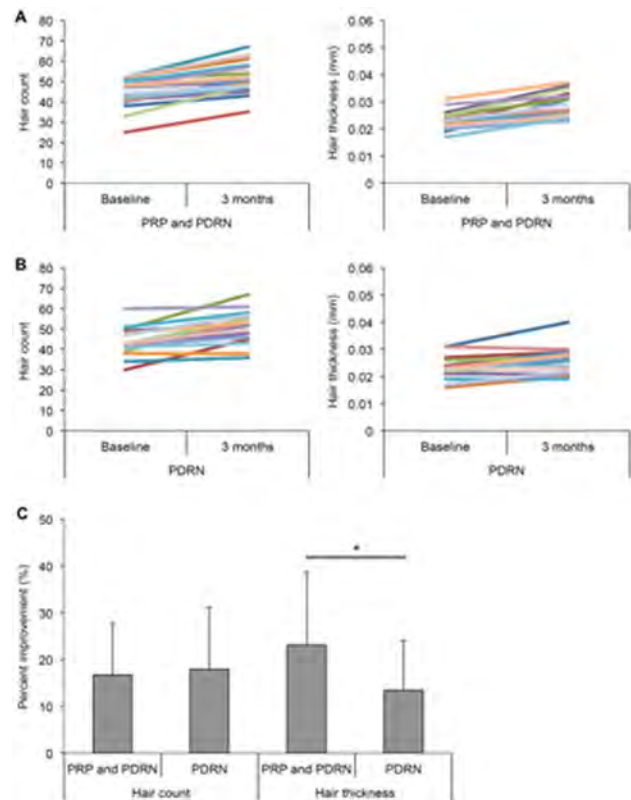


Figure 2. Computerized phototrichogram analyses of hair counts and thickness in patients with female pattern hair loss after combined treatment with intra-perifollicular injections of (A) autologous CD34+ cell-containing, leukocyte-rich preparation and polydeoxyribonucleotide (PDRN) or (B) intra-perifollicular injections of PDRN alone. (C) Percent improvement after treatment with combined platelet-rich plasma (PRP) and PDRN injections, as well as PDRN alone, in hair count and thickness at 3 months, compared with baseline. **p* < 0.05.

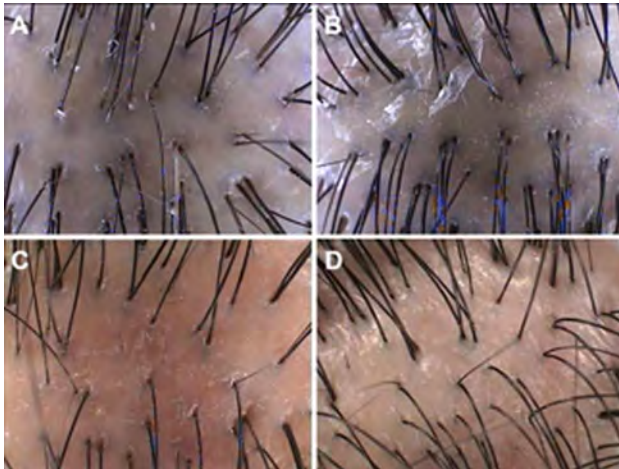


Figure 3. Digital images of the hair at the “V” point in (A, B) patient 1 and (C, D) patient 15 with female pattern hair loss (A, C) before and (B, D) 1 week after the last session of treatment with intra-perifollicular polydeoxyribonucleotide (PDRN) injection alone.

groups suggested that combination therapy with PRP and PDRN injections generates greater improvement in hair thickness ($p = 0.031$), but not in hair counts ($p > 0.05$), than PDRN therapy alone (Figure 2C).

Mean platelet counts in the PRP preparations were $1,256,950 \pm 371,397$ cells/ μ L and mean WBC counts were $19,575 \pm 8,010$ cells/ μ L. Neither platelet counts nor WBC counts were significantly correlated with improvement in hair thickness ($p > 0.05$) or hair counts ($p > 0.05$). In regard to side effects, most of the 20 participants ($n = 18$; 90%) who underwent injections of both PRP and PDRN reported tolerable pain during the procedures; transient posttreatment edema and tenderness after PRP treatment ($n = 4$; 20%), as well as mild itching sensations and desquamation ($n = 2$; 10%), were also reported. The other 20 FPHL patients treated with 12 sessions of PDRN injection alone described tolerable pain during the procedures ($n = 12$; 60%), followed by mild itching sensations and desquamation thereafter ($n = 1$; 10%). Other possible side effects, including progression of FPHL, initial but temporary telogen effluvium, secondary bacterial, fungal, and viral infections, and posttherapy scarring, were not reported.

Effect of autologous PRP injection on WNT expression

A split-back experimental rabbit study was performed to assess the expressions of target mRNA and proteins after injections with PRP and PBS; skin samples were obtained at 1, 3, 5, and 7 weeks after the injections. Time-dependent mRNA and protein expressions of WNT, PDGF, and FGF9 were measured by real-time PCR and Western blotting. The MIXED procedure revealed significantly higher expression of WNT5a mRNA in PRP-treated skin samples than in control skin samples (group X time, $p < 0.001$), especially at 5 weeks

Table 2. Expression of WNT, PDGF, and FGF9 mRNA in rabbits after treatment with platelet-rich plasma injection compared with that with phosphate buffered saline

	p-Value		
	Group	Time	Group X time
WNT5a	$p = 0.012$	$p < 0.001$	$p < 0.001$
WNT10a	$p = 0.002$	$p < 0.001$	$p = 0.003$
PDGF-A	$p = 0.001$	$p < 0.001$	NS
PDGF-B	$p = 0.045$	$p < 0.001$	$p = 0.002$
FGF9	$p < 0.001$	$p < 0.001$	$p < 0.001$

NS, not significant.

(group post hoc test, $p < 0.001$) and 7 weeks (group post hoc test, $p < 0.001$) after treatment (Table 2, Figure 4A). Western blotting showed greater expression of WNT5a protein in PRP-treated skin samples than in control skin samples (group X time, $p < 0.001$) at 1 week (group post hoc test, $p < 0.001$), 3 weeks (group post hoc test, $p = 0.011$), 5 weeks (group post hoc test, $p = 0.028$), and 7 weeks (group post hoc test, $p = 0.019$) after treatment (Table 3, Figure 5A).

Additionally, statistical analysis using the MIXED procedure also revealed significantly higher expression of WNT10a mRNA in PRP-treated skin samples than in control skin samples (group X time, $p = 0.003$) at 1 week (group post hoc test, $p < 0.001$), 3 weeks (group post hoc test, $p < 0.001$), 5 weeks (group post hoc test, $p = 0.008$), and 7 weeks (group post hoc test, $p < 0.001$) after treatment (Table 2, Figure 4B). Meanwhile, Western blotting showed greater expression of

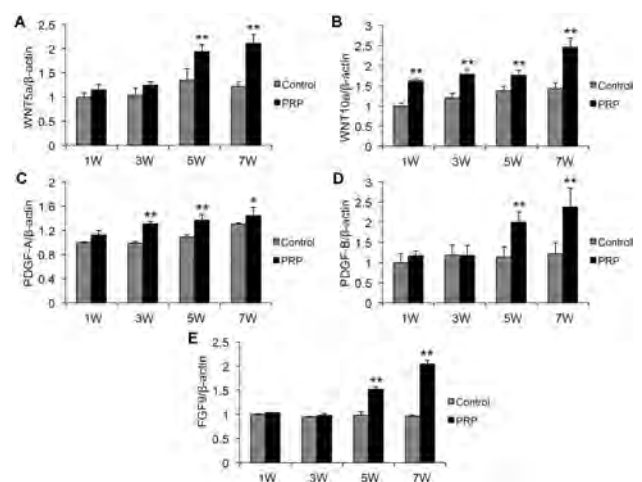


Figure 4. Real-time polymerase chain reaction analyses of (A) WNT5a, (B) WNT10a, (C) PDGF-A, (D) PDGF-B, and (E) FGF9 mRNA levels in rabbit skin samples obtained at 1, 3, 5, and 7 weeks after intra-perifollicular injections of platelet-rich plasma (PRP). * $p < 0.05$; ** $p < 0.01$.

Table 3. Expression of WNT, PDGF, and FGF9 protein in rabbits after treatment with platelet-rich plasma injection compared with that with phosphate buffered saline

	p-Value		
	Group	Time	Group X time
WNT5a	$p = 0.028$	$p < 0.001$	$p < 0.001$
WNT10a	NS	$p < 0.001$	$p = 0.002$
PDGF-A	NS	$p < 0.001$	$p = 0.002$
PDGF-B	NS	$p = 0.002$	$p = 0.004$
FGF9	$p = 0.004$	$p < 0.001$	$p < 0.001$

NS, not significant.

WNT10a protein in PRP-treated skin samples than in the control skin samples (group X time, $p = 0.002$) at 3 weeks (group post hoc test, $p = 0.015$) and 7 weeks (group post hoc test, $p = 0.01$) (Table 3, Figure 5B).

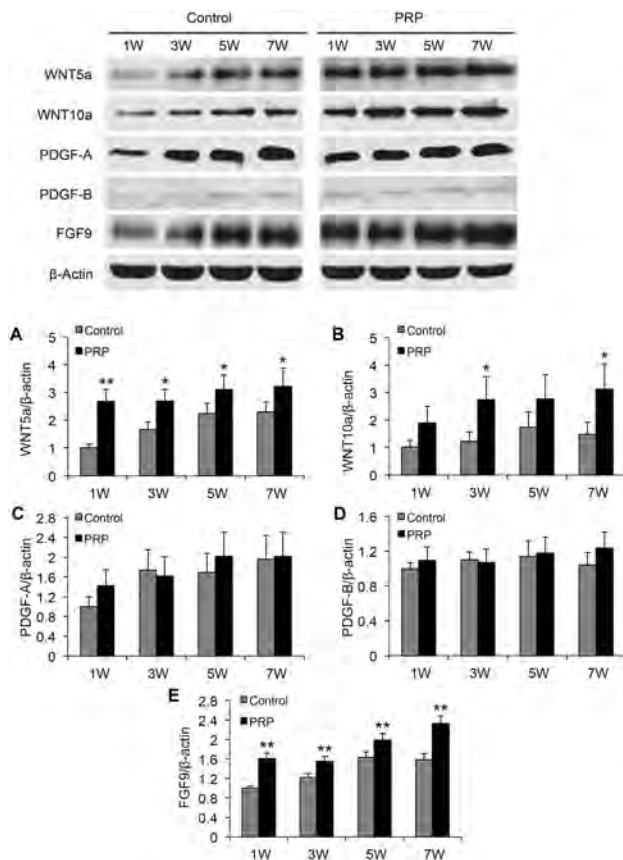


Figure 5. Western blotting analyses of (A) WNT5a, (B) WNT10a, (C) PDGF-A, (D) PDGF-B, and (E) FGF9 protein levels in rabbit skin samples obtained at 1, 3, 5, and 7 weeks after intra-perifollicular injections of platelet-rich plasma (PRP). * $p < 0.05$; ** $p < 0.01$.

Effect of autologous PRP injection on PDGF and FGF9 expression

Real-time PCR analyses of rabbit skin samples showed that PRP treatment significantly increases PDGF-A mRNA expression, compared with controls, at 3 weeks (group post hoc test, $p < 0.001$), 5 weeks (group post hoc test, $p < 0.001$), and 7 weeks (group post hoc test, $p = 0.04$) (Figure 4C); however, upon analysis with the MIXED procedure, which analyzed results in relation to treatment group and time sequence, differences in PDGF-A mRNA expression were not statistically significant ($p > 0.05$). Additionally, Western blot analyses of PDGF-A revealed significant differences between PRP-treated skin samples and control skin samples (group X time, $p = 0.002$) (Table 3). The MIXED procedure showed significantly higher expression of PDGF-B mRNA in PRP-treated skin samples than in control skin samples (group X time, $p = 0.002$), especially at 5 weeks (group post hoc test, $p = 0.004$) and 7 weeks (group post hoc test, $p < 0.001$) after the treatment (Table 2, Figure 4D). PDGF-B protein expression was also significantly different between PRP-treated skin samples and control skin samples (group X time, $p = 0.004$) (Table 3).

Among skin samples obtained from the halves of the backs of rabbits injected with PRP, FGF9 mRNA was significantly up-regulated, compared with the control side (group X time, $p < 0.001$; group post hoc test at 5 weeks, $p < 0.001$; and group post hoc test at 7 weeks, $p < 0.001$) (Table 2, Figure 4E). Also, Western blotting revealed greater expression of FGF9 protein in PRP-treated skin samples than in control skin samples (group X time, $p < 0.001$) at 1 week (group post hoc test, $p < 0.001$), 3 weeks (group post hoc test, $p = 0.003$), 5 weeks (group post hoc test, $p = 0.002$), and 7 weeks (group post hoc test, $p < 0.001$) after treatment (Table 3, Figure 5E).

DISCUSSION

Hair follicles are generated upon serial expressions and interactions of various follicular signals from the epithelium and mesenchyme.¹³ By modulating the WNT signaling activity, the fate of hair follicle stem cells could be determined between maintaining stemness and hair regeneration.¹⁴ Among several key signals, WNT signals are required for the initiation of follicle development, and WNTs 10a and 10b act as the first epidermal signals of the canonical WNT/ β -catenin signaling pathway.^{13,15} Additionally, WNT5a gene expression is dependent on the expression of Sonic hedgehog, which is positively regulated by WNT10b gene expression and found in developing dermal condensates.¹³ Histologically, WNT10a is expressed in inner root sheath (IRS) cells, whereas WNT5a is expressed at low levels in the dermal papilla and at high levels in the outer root sheath and outer layers of the IRS.¹³ In the present study, we discovered significant group- and time-dependent differences in the expression of WNT5a mRNA and protein, as well as WNT10a mRNA and protein, which were higher among skin samples obtained from the backs of rabbits treated with PRP injections than those treated with PBS.

Current clinical and experimental investigations into the treatment of pattern hair loss have mainly addressed follicular stem cell activation and cellular differentiation during the hair growth cycle.¹⁶ Festa et al.¹⁷ demonstrated that intradermal

adipocyte lineage cells drive follicular stem cell activation in mammalian skin and that the regulation of follicular stem cell activity is positively regulated by PDGF expression in immature adipocytes.¹⁷ Additionally, other clinical reports have described the recovery of secondary alopecia lesions after autologous fat transplantation, the mechanisms of which were proposed as being related to a greater ability for adipose-derived stem cells to undergo multilineage differentiation.^{18,19} Nevertheless, application of autologous fat transplantation in the treatment of pattern hair loss requires tremendous experience with surgical harvesting and grafting techniques and, moreover, lacks sufficient evidence for its use. In this pilot animal study, we found that the expression of PDGF-A mRNA was significantly up-regulated at 3 weeks, 5 weeks, and 7 weeks after PRP treatment, compared with controls, and that PDGF-B mRNA expression markedly increased at 5 weeks and 7 weeks post-PRP injection. These results suggest that PRP injections, which are relatively easy to administer, may be of use in treating FPHL by inducing PDGF expression in immature adipocytes of alopecia lesions.

During wound healing of the skin, dermal $\gamma\delta$ T cells produce FGF9, which triggers WNT expression and results in hair follicle regeneration.²⁰ Accordingly, up-regulation of FGF9 expression enhances follicular neogenesis in skin wounds, while down-regulation of this protein decreases new follicle formation.²⁰ Real-time PCR analyses of a wound-induced hair neogenesis mouse model showed that FGF9 expression increases significantly on postwound day 10 in wounded dermis tissue.²⁰ In the present study, we also observed significant up-regulation of FGF9 mRNA and protein upon injections of PRP, without making an excisional wound, along the backs of rabbits, compared with the control side. However, marked increases in FGF9 mRNA expression were found at 5 and 7 weeks after PRP treatment, and increased expression of FGF9 protein was observed at 1, 3, 5, and 7 weeks posttreatment.

In the early phases of PRP treatment, before angiogenesis, hair follicles obtain growth factors and nutritional elements from the injected PRP.²¹ Previous studies showed that slower and more efficient release of growth factors from concentrated platelets and leukocytes was obtained by using endogenous activation, rather than prior activation, of PRP preparation.^{22–24} Additionally, leukocyte-rich PRP preparations without prior activation showed steady increases in PDGF-AB over storage times of 120 hours.²² In the late phases of PRP treatment, after vascularization, sufficient cellular component and signaling molecules (induced by PRP injections) can be obtained from the injection sites for folliculoneogenesis.^{4,21} In this study, we found that WNT, PDGF, and FGF were highly expressed in PRP-treated animal skin up to 7 weeks after injection, compared with control skin. We suggest that differences between human skin and rabbit skin, which is thinner and more fibrotic, may account for the prolonged expression of these growth factors.

Finally, our data suggest that intra-perifollicular injection of autologous CD34+ cell-containing, leukocyte-rich PRP and/or PDRN improves hair thickness and density in FPHL patients. Additionally, our pilot animal study showed that the expressions of WNT, PDGF, and FGF are significantly up-regulated in rabbit skin treated with PRP. Although our laboratory data may not fully reflect clinical conditions, we suggest that our results from the pilot animal study support, in part, our clinical results of PRP treatment for hair regenera-

tion. Nevertheless, further prospective studies with a controlled/split human scalp design should be conducted to confirm the clinical efficacy of autologous CD34+ cell-containing, leukocyte-rich PRP treatment in patients with pattern hair loss.

ACKNOWLEDGMENTS

We would like to thank Hye Sun Lee, PhD (Department of Biostatistics, Yonsei University College of Medicine, Seoul, Korea) for her help with the statistical analyses. Also, we would like to thank Anthony Thomas Milliken, ELS, at Editing Synthese (<http://editingsynthese.com>) for his help with the editing of this manuscript.

Source of Funding: None.

Conflicts of Interest: The authors declare no conflicts of interest.

REFERENCES

- Atanaskova Mesinkovska N, Bergfeld WF. Hair: what is new in diagnosis and management? Female pattern hair loss update: diagnosis and treatment. *Dermatol Clin* 2013; 31: 119–27.
- Olsen EA. Female pattern hair loss. *J Am Acad Dermatol* 2001; 45: S70–80.
- Oh DS, Cheon YW, Jeon RY, Lew DH. Activated platelet-rich plasma improves fat graft survival in nude mice: a pilot study. *Dermatol Surg* 2011; 37: 619–25.
- Uebel CO, da Silva JB, Cantarelli D, Martins P. The role of platelet plasma growth factors in male pattern baldness surgery. *Plast Reconstr Surg* 2006; 118: 1458–66.
- Takikawa M, Nakamura S, Nakamura S, Ishirara M, Kishimoto S, Sasaki K, et al. Enhanced effect of platelet-rich plasma containing a new carrier on hair growth. *Dermatol Surg* 2011; 37: 1721–9.
- Li ZJ, Choi HI, Choi DK, Sohn KC, Im M, Seo YJ, et al. Autologous platelet-rich plasma: a potential therapeutic tool for promoting hair growth. *Dermatol Surg* 2012; 38: 1040–6.
- Park KY, Kim HK, Kim BJ, Kim MN. Letter: platelet-rich plasma for treating male pattern baldness. *Dermatol Surg* 2012; 38: 2042–4.
- Kang JS, Zheng Z, Choi MJ, Lee SH, Kim DY, Cho SB. The effect of CD34+ cell-containing autologous platelet-rich plasma injection on pattern hair loss: a preliminary study. *J Eur Acad Dermatol Venereol* 2014; 28: 72–9.
- Chen TM, Tsai JC, Burnouf T. A novel technique combining platelet gel, skin graft, and fibrin glue for healing recalcitrant lower extremity ulcers. *Dermatol Surg* 2010; 36: 453–60.
- Lee JW, Kim BJ, Kim MN, Mun SK. The efficacy of autologous platelet-rich plasma combined with ablative carbon dioxide fractional resurfacing for acne scars: a simultaneous split-face trial. *Dermatol Surg* 2011; 37: 931–8.
- Landesberg R, Roy M, Glickman RS. Quantification of growth factor levels using a simplified method of platelet-rich plasma gel preparation. *J Oral Maxillofac Surg* 2000; 58: 297–301.
- Weibrich G, Kleis WK, Hafner G. Growth factor levels in the platelet-rich plasma produced by 2 different methods: curas-type PRP kit versus PCCS PRP system. *Int J Oral Maxillofac Implants* 2002; 17: 184–90.
- Reddy S, Andl T, Bagasra A, Lu MM, Epstein DJ, Morrisey EE, et al. Characterization of *Wnt* gene expression in developing and postnatal hair follicles and identification of *Wnt5a* as a target of

- Sonic hedgehog in hair follicle morphogenesis. *Mech Dev* 2001; 107: 69–82.
14. [Lien WH, Polak L, Lin M, Lay K, Zheng D, Fuchs E. In vivo transcriptional governance of hair follicle stem cells by canonical Wnt regulators. *Nat Cell Biol* 2014; 16: 179–90.](#)
 15. [Andl T, Reddy ST, Gaddapara T, Millar SE. WNT signals are required for the initiation of hair follicle development. *Dev Cell* 2002; 2: 643–53.](#)
 16. [Semalaty M, Semalaty A, Joshi GP, Rawat MS. Hair growth and rejuvenation: an overview. *J Dermatolog Treat* 2011; 22: 123–32.](#)
 17. [Festa E, Fretz J, Berry R, Schmidt B, Rodeheffer M, Horowitz M, et al. Adipocyte lineage cells contribute to the skin stem cell niche to drive hair cycling. *Cell* 2011; 146: 761–71.](#)
 18. [Coleman SR. Structural fat grafting: more than a permanent filler. *Plast Reconstr Surg* 2006; 118: 108S–20.](#)
 19. [Cho SB, Roh MR, Chung KY. Recovery of scleroderma-induced atrophic alopecia by autologous fat transplantation. *Dermatol Surg* 2010; 36: 2061–3.](#)
 20. [Gay D, Kwon O, Zhang Z, Spata M, Plikus MV, Holler PD, et al. Fgf9 from dermal \$\gamma\delta\$ T cells induces hair follicle neogenesis after wounding. *Nat Med* 2013; 19: 916–23.](#)
 21. [Miao Y, Sun YB, Sun XJ, Du BJ, Jiang JD, Hu ZQ. Promotional effect of platelet-rich plasma on hair follicle reconstitution in vivo. *Dermatol Surg* 2013; 39: 1868–76.](#)
 22. [Leitner GC, Gruber R, Neumüller J, Wagner A, Kloimstein P, Höcker P, et al. Platelet content and growth factor release in platelet-rich plasma: a comparison of four different systems. *Vox Sang* 2006; 91: 135–9.](#)
 23. [Davis VL, Abukabda AB, Radio NM, Witt-Enderby PA, Clafshenkel WP, Cairone JV, et al. Platelet-rich preparations to improve healing. Part II: platelet activation and enrichment, leukocyte inclusion, and other selection criteria. *J Oral Implantol* 2014; 40: 511–21.](#)
 24. [Clark RA, Lanigan JM, DellaPelle P, Manseau E, Dvorak HF, Colvin RB. Fibronectin and fibrin provide a provisional matrix for epidermal cell migration during wound reepithelialization. *J Invest Dermatol* 1982; 79: 264–9.](#)